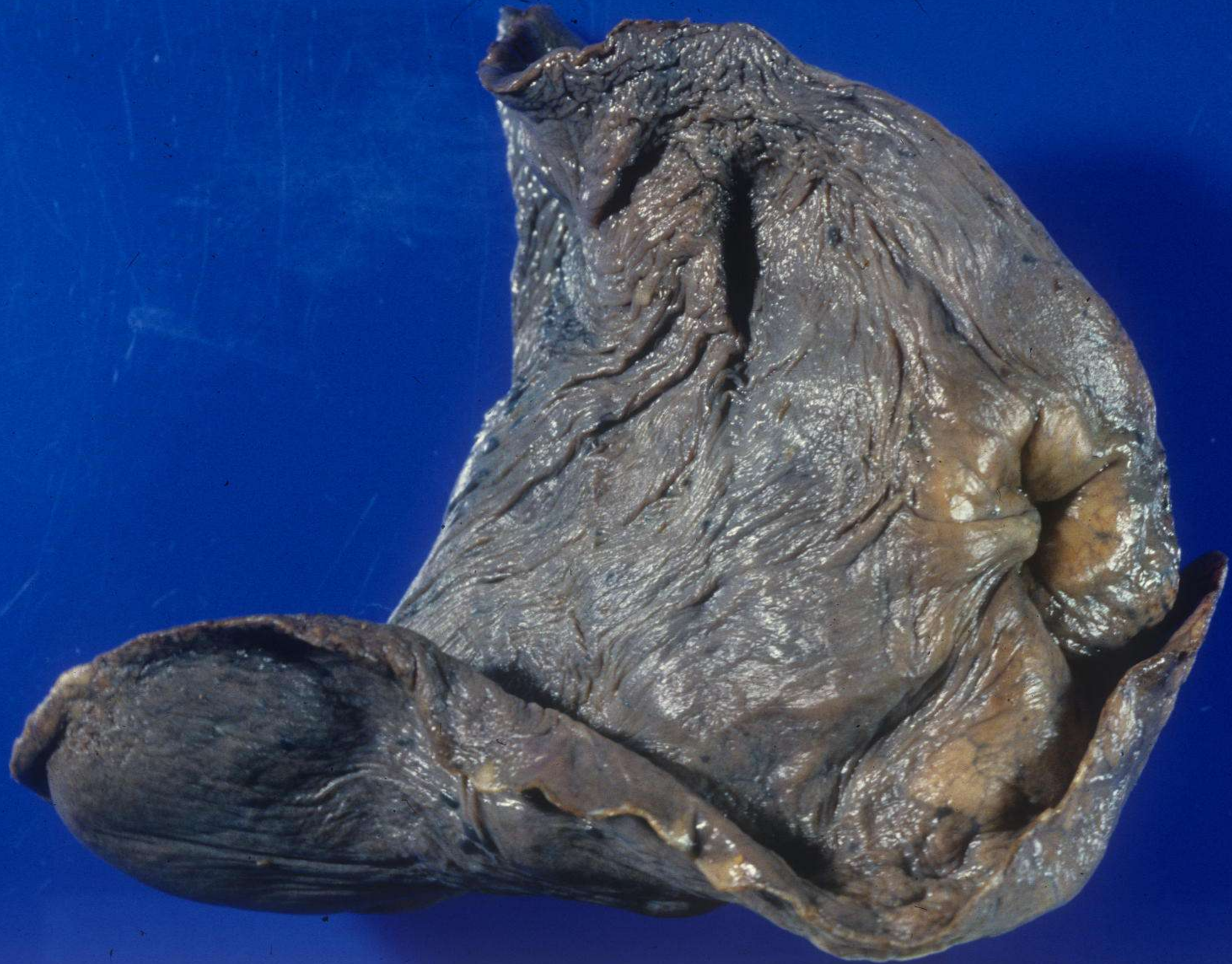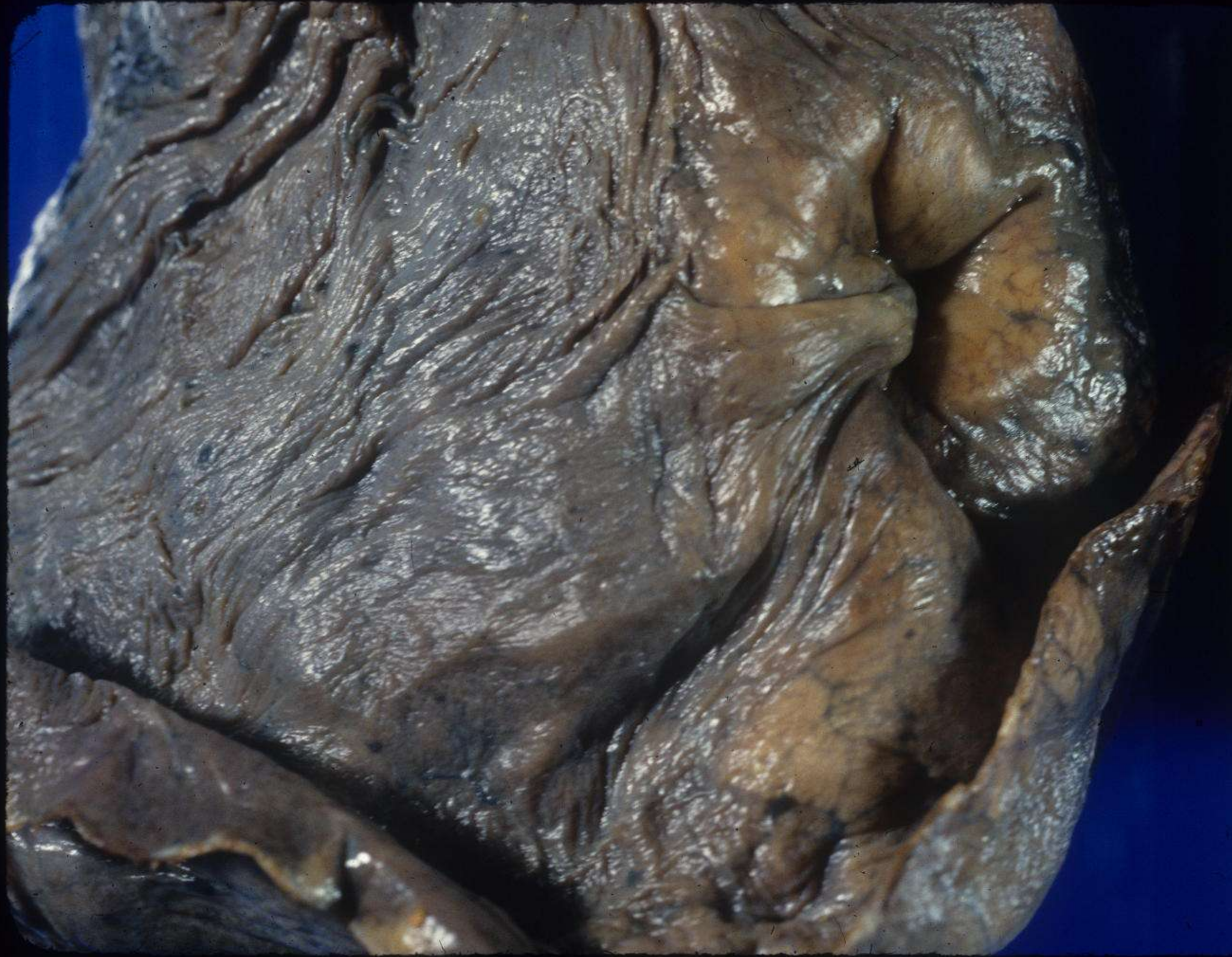

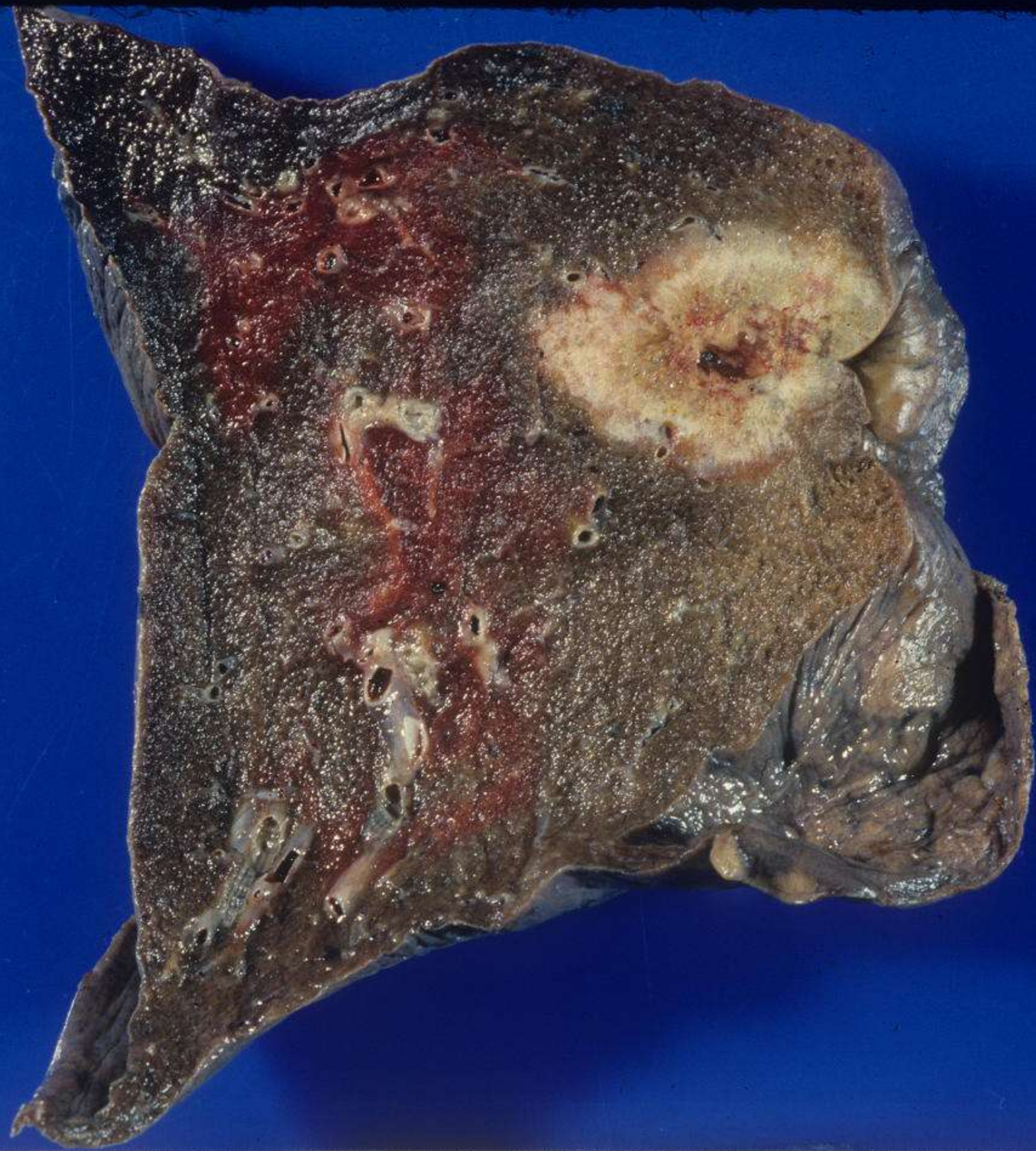


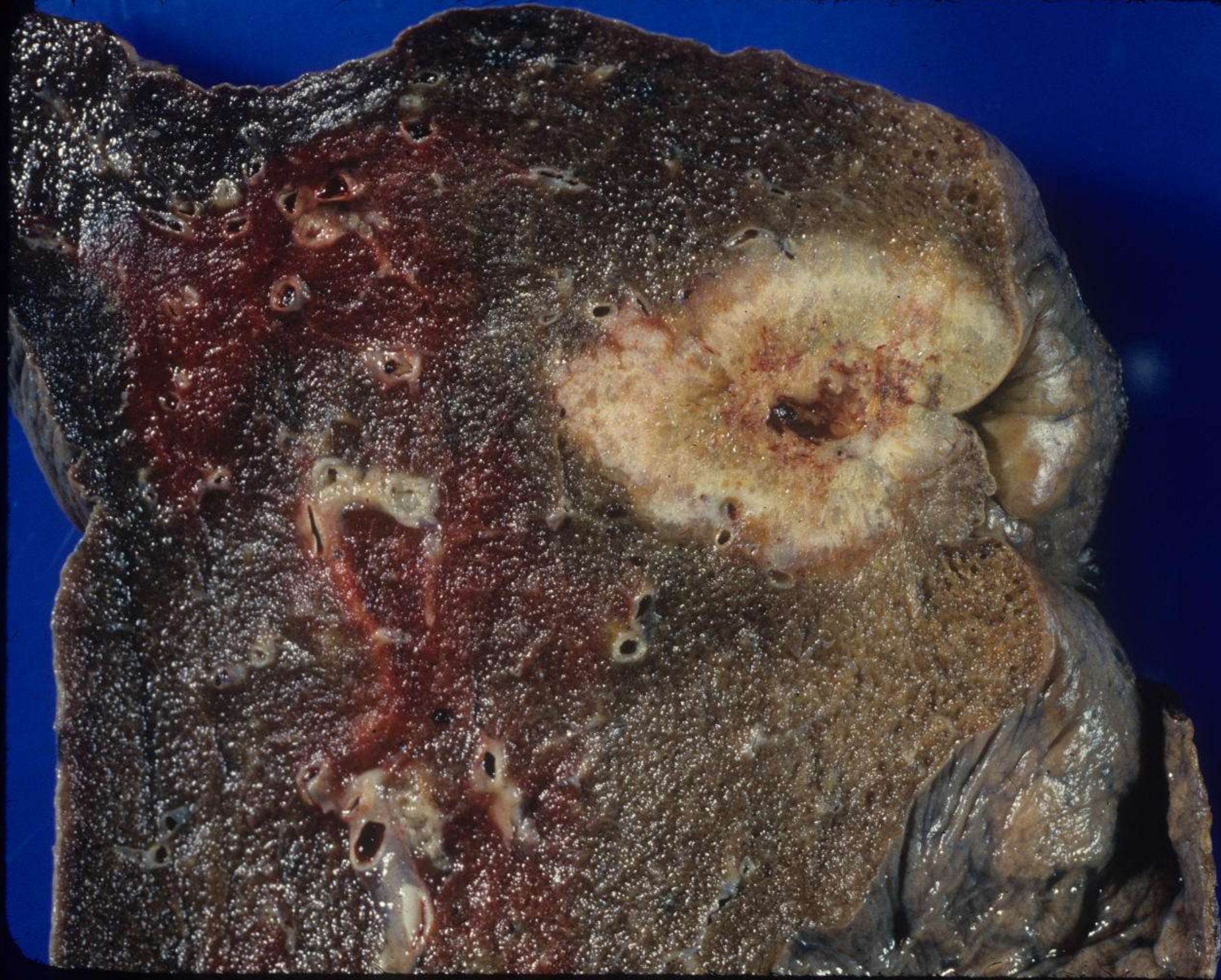S85-31308



S85-31308



585-31308



S85-31308



A gross pathology specimen of a lung, showing a large, pale, lobulated mass in the lower lobe. The mass is surrounded by a thick, dark, fibrous capsule. The lung parenchyma is dark brown and appears consolidated. The specimen is placed on a blue background with a ruler for scale.

S85-31308